

Clinical Case Seminar

A8(1-6)

A single bone lesion in a man with prostate cancer: a case report of Paget's disease of bone.

¹Federica Bellone, ¹Nunziata Morabito, ¹Annamaria Pugliese, ²Gabriella Martino, ¹Antonino Catalano

¹ Department of Clinical and Experimental Medicine, University Hospital of Messina Messina, Italy;

²Department of Cognitive Sciences, Psychology, Education and Cultural Studies, University of Messina, Messina, Italy

Abstract

Paget's disease of bone (PDB) is the second most common type of bone disease after osteoporosis. It should be considered in the differential diagnosis of bone lesions in elderly men with prostate cancer and single bone involvement, especially if increased serum levels of alkaline phosphatase coexist. We present the clinical case of a patient with moderate chronic renal failure who was diagnosed with prostate cancer, later treated surgically. He presented a bone lesion at the left hemipelvis for which the suspected PDB was confirmed by biopsy. The aminobisphosphonate neridronate has been administered with a cumulative dose of 200 mg, as a medical treatment of PDB. Due to the potential nephrotoxicity of the aminobisphosphonates such as neridronate in patient with reduced glomerular filtration rate (GFR), an alternative treatment of the PDB with denosumab, a fully human monoclonal antibody that binds RANKL, has been discussed and proposed, in case of relapse of PDB and further deterioration of GFR.

Key-Words: Paget's disease; prostate cancer; renal failure; neridronate; denosumab.

Introducing Member: Antonino Catalano

Corresponding Author: Federica Bellone - federicabellone@hotmail.it

Introduction

Paget's disease of bone (PDB) is the second most common type of bone metabolic disorder after osteoporosis [1]. PDB represents a chronic focal bone remodelling disease which often results in enlarged and deformed bones in single or multiple regions of the skeleton. Data from clinical, radiological and necropsy observations suggest different PDB prevalence according to different countries, up to 3-5% in Britain; while PDB prevalence in Italy, is at least 1%, comparable with American and European observations [2].

Prostate cancer is the most common malignant neoplasm in men and it is the second leading cause of male cancer-related death [3]. Bone metastases are commonly observed in advanced prostate cancer and may lead to skeletal-related events [4]. High levels of alkaline phosphatase (ALP) may be an important laboratory sign of bone metastases in patients with prostate cancer, but may also be a marker of PDB [2,5].

Sometimes PDB coexists with prostate cancer and this may lead to a doubt in diagnosis compared to bone metastases secondary to prostate cancer [6].

We describe the case of an elderly man with prostate cancer and PDB, whose treatment has been considered according with kidney failure, a relevant comorbid condition in aging men.

Case presentation

A 72 years-old man with a history of high blood pressure and type 2 diabetes has been received in our Outpatient Clinic at the Department of Internal Medicine of University Hospital of Messina to perform a fracture risk assessment due to a recently detected osteopenia at a dual-energy X-ray absorptiometry [7]. After clinical and laboratory evaluation, including prostate specific antigen, a diagnosis of prostate cancer (Gleason score 3+4) was formulated and a surgical treatment was successfully soon after carried out. Further evaluations with whole body computed tomography, X-ray and bone scintigraphy were able to identify a wide bone lesion at the left hemipelvis which raised the doubt of bone metastasis from prostate cancer (**Figure 1** and **Figure 2**). By considering a high serum ALP level, Paget's disease of bone (PDB) was also considered and a bone biopsy confirmed this diagnosis. A further assessment with renal scintigraphy was performed, showing a glomerular filtration rate (GFR) of 38 ml/min and it was administered neridronate, in accordance with previous published data [1]. Over the next four months, in order to minimize the risk of nephrotoxicity, a cumulative dose of 200 mg neridronate was administered (25 mg i.m bimonthly) Vitamin D status correction was obtained with a large oral dose of cholecalciferol (300,000 UI) followed by maintenance dose of 25.000 UI bimonthly. ALP levels decreased and maintained within the normal range at follow up at 4 and 12 months (**Table 1**).

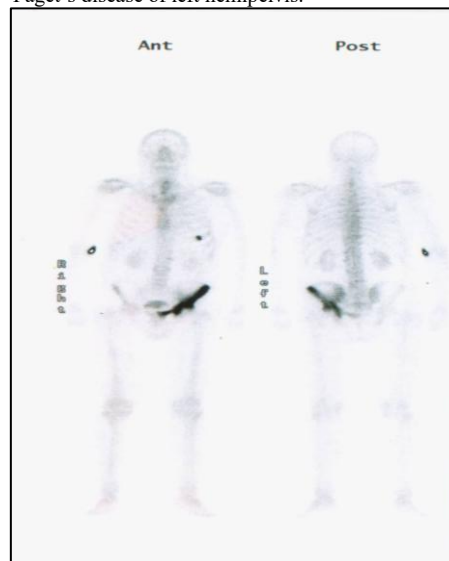
Tab.1. Main laboratory findings.

	Creatinine (vn 0.6-1.2 mg/dl)	Calcium (vn 8.2-10.4 mg/dl)	Phosphorus (vn 2.5-4.6 mg/dl)	ALP (vn 40-150 UI/l)	PTH (vn 12-72 pg/ml)	25(OH)D (vn >30 ng/ml)
Baseline	1.7	9.4	3	240	34.9	17.1
Month 1	1.5	8.8	2.8	198		
Month 4	1.6	8.9	3.2	70	20.3	48.2
Month 12	1.6	9.62	3.6	78	27	25.2

Fig 1. X-ray of a prostate cancer patient with Paget's disease of left hemipelvis

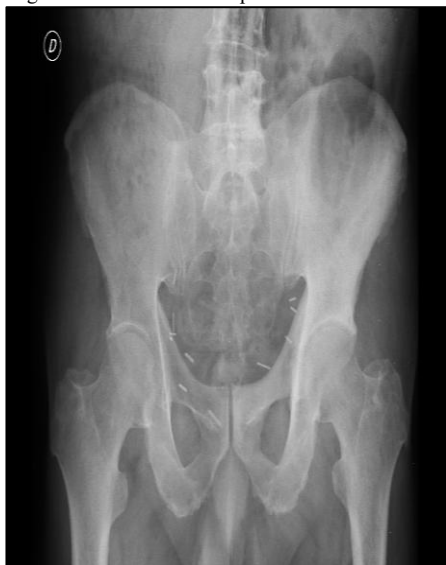

Fig 2. Total body bone scintigraphy showing a Paget's disease of left hemipelvis.



Discussion

The case described provides clinician some insights. First, bisphosphonates are a class of anti-resorptive agents approved to treat multiple skeletal disorders including osteoporosis, malignancy-associated bone disease and PDB. Bisphosphonate treatment, particularly at higher dose, could be associated with renal function deterioration and cases of acute kidney failure have been reported among patients who received rapid injections of zoledronic acid for bone metastases treatment [8,9]. We avoided use of large doses of neridronate (e.g. 100 mg i.v.) in favour of repeated low doses of 25 mg i.m. over time. In comparison with the treatment schedule by Merlotti et al. [1], which involves weekly administration of i.m. neridronate, we used neridronate every 14 days to possibly reduce the risk of kidney injury due to close repeated doses [10]. Neridronate is included in the Italian guideline for the treatment of PDB and was not previously associated with kidney failure. Moreover, i.m. administration allowed the patient to carry out home therapy, thus avoiding further hospitalization [11]. A GFR of 30 ml/min at least is required to administer bisphosphonates without increasing the risk of nephrotoxicity [8]. Our patient showed a poor vitamin D status [12]. Therefore, large oral dose of cholecalciferol was administered before neridronate treatment both to correct hypovitaminosis D and to contrast the possible rise of an acute phase response due to aminobisphosphonate injection, as previously described [13]. We also argued a possible alternative treatment in case of relapse of PDB represented by denosumab (Dmab). As known, interaction of osteoprotegerin, receptor activator of nuclear factor-kappa B (RANK) with RANK ligand (RANKL), is crucial for the regulation of bone

remodeling [14,15].

RANKL is the most potent controller of osteoclast formation and activity. As known, Dmab is a fully human monoclonal antibody which binds RANKL [16]. Subcutaneous Dmab injections every 6 months significantly reduces the risk of vertebral, nonvertebral, and hip fractures, by increasing bone mineral density and reducing surrogate markers of bone turn-over [7,16,17]. The interesting datum would be to understand the reasons why Dmab may represent an alternative treatment of PDB in cases where neridronate is contraindicated.

Efficacy of Dmabis independent of the degree of renal impairment also including patients in chronic kidney disease stage 4 [18]. Moreover, the ratio between RANKL and osteoprotegerin -its decoy receptor- was more than 3-fold higher in PDB patients than in controls. Thus, Dmab, blocking RANKL, could be reasonably indicated as a potential innovative treatment of this bone disorder [19,20]. New evidences are consistent with the use of Dmab as a second line of treatment of PDB in specific contexts [21,22].

Finally, association of prostate cancer and PDB is a mere casualty? Etiology of PDB is unknown, but mutations in the SQSTM1/p62 gene have been identified in up to 30% of PDB patients [23]. Mutations in the same gene are also observed in patients with prostate cancer, even if the causality of these mutations towards prostate cancer or PDB remains to be clarified [24].

In conclusion, PDB is a focal disorder of bone remodelling characterized by an increased osteoclast-mediated bone resorption. PDB may be asymptomatic, as in the described clinical case, but it should be burdened from increased fracture risk possibly impairing patient's perceived quality of life [25]. PDB could simulate osteoblastic bone metastases in prostate cancer patient and an accurate diagnostic work-up should be carried out. Neridronate has been confirmed to be safe and effective in the treatment of PDB also when moderate renal kidney failure coexists. However, due to the possible nephrotoxicity of aminobisphosphonates in subjects with renal function deterioration, an alternative treatment of PDB with Dmab could be considered.

Conflicts of Interest: There is no potential conflict of interest, and the authors have nothing to disclose. This work was not supported by any grant.

References

1. Merlotti, D., Rendina, D., Gennari, L., Mossetti, G., Gianfrancesco, F., Martini, G., De Filippo, G., Avanzati, A., Franci, B., Campagna, M.S., Strazzullo, P., Nuti, R. (2011) Comparison of intravenous and intramuscularneridronateregimens for the treatment of Pagetdisease of bone. *J Bone Miner Res* 26(3):512-51
2. Gennari, L., Di Stefano, M., Merlotti, D., Giordano, N., Martini, G., Tamone, C., Zatterli,

- R., De Lucchi, R., Baldi, C., Vattimo, A., Capoccia, S., Burrioni, L., Geraci, S., De Paola, V., Calabrò, A., Avanzati, A., Isaia, G., Nuti, R. (2005) Prevalence of Paget's disease of bone in Italy. *J Bone Miner Res* 20(10):1845-1850
3. Morabito, N., Gaudio, A., Lasco, A., Catalano, A., Atteritano, M., Trifiletti, A., Anastasi, G., Melloni, D., Frisina, N. (2004) Neridronate prevents bone loss in patients receiving androgen deprivation therapy for prostate cancer. *J Bone Miner Res* 19(11):1766-1770.
 4. Miller, P.D., Eardley, I., Kirby, R.S. (1992) Prostate specific antigen and bone scan correlation in the staging and monitoring of patients with prostatic cancer. *Br J Urol* 70(3):295-298
 5. Metwalli, A.R., Rosner, I.L., Cullen, J., Chen, Y., Brand, T., Brassell, S.A., Lesperance, J., Porter, C., Sterbis, J., McLeod, D.G. (2014) Elevated alkaline phosphatase velocity strongly predicts overall survival and the risk of bone metastases in castrate-resistant prostate cancer. *Urol Oncol* 32(6):761-768
 6. Sirikulchayanonta, S., Jaovisidha, S., Kongchareonsombat, W., Sirikulchayanonta, V. (2014) Paget's disease of bone in ethnic Thai presented with urologic symptoms and misleading as metastatic prostate cancer: report of a case with a review of the literature. *J Med Assoc Thai* 97(6):673-677
 7. Catalano, A., Gaudio, A., Morabito, N., Basile, G., Agostino, R.M., Xourafa, A., Atteritano, M., Morini, E., Natale, G., Lasco, A. (2017) Quantitative ultrasound and DXA measurements in aromatase inhibitor-treated breast cancer women receiving denosumab. *J Endocrinol Invest* 40(8):851-857
 8. Perazella, M.A., Markowitz, G.S. (2008) Bisphosphonate nephrotoxicity. *Kidney Int* 74:1385-1393
 9. Chang, J.T., Green, L., Beitz, J. (2003) Renal failure with the use of zoledronic acid. *N Engl J Med* 349:1676-1679
 10. Bergner, R., Siegrist, B., Gretz, N., Pohlmeier-Esch, G., Kränzlin, B. (2015) Nephrotoxicity of ibandronate and zoledronate in Wistar rats with normal renal function and after unilateral nephrectomy. *Pharmacol Res* 99:16-22
 11. Adami S, Bartolozzi P, Brandi ML, Falchetti A, Filippini P, Gonnelli S, Bianchi G, Isaia GC, Nuti R; Collegio Reumatologi Ospedalieri Italiani; Società Italiana di Medicina Interna; Società Italiana di Ortopedia e Traumatologia; Società Italiana di Osteoporosi e Malattie del Metabolismo Minerale e Scheletrico; Società Italiana di Reumatologia. (2007) Italian guidelines for the diagnosis and treatment of Paget's disease of bone. *Reumatismo* 59(2):153-168
 12. Martino, G., Catalano, A., Bellone, F., Sardella, A., Lasco, C., Caprì, T., Langher, V., Caputo, A., Fabio, R.A., Morabito, N. (2018) Vitamin D status is associated with anxiety levels in postmenopausal women evaluated for osteoporosis. *Mediterranean Journal of Clinical Psychology* 6(1): 1-16
 13. Catalano, A., Morabito, N., Atteritano, M., Basile, G., Cucinotta, D., Lasco, A. (2012) Vitamin D reduces musculoskeletal pain after infusion of zoledronic acid for postmenopausal osteoporosis. *Calcif Tissue Int* 90(4):279-285
 14. Gaudio, A., Lasco, A., Morabito, N., Atteritano, M., Vergara, C., Catalano, A., Fries, W., Trifiletti, A., Frisina, N. (2005) Hepatic osteodystrophy: does the osteoprotegerin/receptor activator of nuclear factor- κ B ligand system play a role? *J Endocrinol Invest* 28(8):677-682
 15. Morabito, N., Russo, G.T., Gaudio, A., Lasco, A., Catalano, A., Morini, E., Franchina, F., Maisano, D., La Rosa, M., Plota, M., Crifò, A., Meo, A., Frisina, N. (2007) The "lively" cytokines network in beta-Thalassemia Major-related osteoporosis. *Bone* 40(6):1588-1594
 16. Scott, L.J. (2014) Denosumab: a review of its use in postmenopausal women with osteoporosis. *Drugs Aging* 31(7):555-576
 17. Lasco, A., Morabito, N., Basile, G., Atteritano, M., Gaudio, A., Giorgianni, G.M., Morini, E., Faraci, B., Bellone, F., Catalano, A. (2016) Denosumab Inhibition of RANKL and Insulin Resistance in Postmenopausal Women with Osteoporosis. *Calcif Tissue Int* 98(2):123-128
 18. Jamal, S.A., Ljunggren, O., Stehman-Breen, C., Cummings, S.R., McClung, M.R., Goemaere, S., Ebeling, P.R., Franek, E., Yang, Y.C., Egbuna, O.I., Boonen, S., Miller, P.D. (2011) Effects of denosumab on fracture and bone mineral density by level of kidney

function. *J Bone Miner Res* 26:1829-1835

19. Martini, G., Gennari, L., Merlotti, D., Salvadori, S., Franci, M.B., Campagna, S., Avanzati, A., De Paola, V., Valleggi, F., Nuti, R. (2007) Serum OPG and RANKL levels before and after intravenous bisphosphonate treatment in Paget's disease of bone. *Bone* 40(2):457-463
20. Schwarz, P., Rasmussen, A.Q., Kvist, T.M., Andersen, U.B., Jorgensen, N.R. (2012) Paget's disease of the bone after treatment with Denosumab: a case report *Bone* 50(5):1023-1025
21. Reid, I.R., Sharma, S., Kalluru, R., Eagleton, C. (2016) Treatment of Paget's Disease of Bone with Denosumab: Case Report and Literature Review. *Calcif Tissue Int* 99(3):322-325
22. Polyzos, S.A., Singhellakis, P.N., Naot, D., Adamidou, F., Malandrinou, F., Anastasilakis, A.D., Polymerou, V., Kita M. (2014) Denosumab treatment for juvenile Paget's disease: results from two adult patients with osteoprotegerin deficiency ("Balkan" mutation in the TNFRSF11B gene). *J ClinEndocrinolMetab* 99(3):703-707
23. Rea, S.L., Walsh, J.P., Ward, L., Magno, A.L., Ward, B.K., Shaw, B., Layfield, R., Kent, G.N., Xu, J., Ratajczak, T. (2009) Sequestosome 1 mutations in Paget's disease of bone in Australia: prevalence, genotype/phenotype correlation, and a novel non-UBA domain mutation (P364S) associated with increased NF-kappaB signaling without loss of ubiquitin binding. *J Bone Miner Res* 24(7):1216-1223
24. Chang, M.A., Morgado, M., Warren, C.R., Hinton, C.V., Farach-Carson, M.C., Delk, N.A. (2014) p62/SQSTM1 is required for cell survival of apoptosis-resistant bone metastatic prostate cancer cell lines. *Prostate* 74(2):149-163
25. Catalano, A., Martino, G., Morabito, N., Scarcella, C., Gaudio, A., Basile, G., Lasco, A. (2017) Pain in Osteoporosis: From Pathophysiology to Therapeutic Approach. *Drugs Aging* 34(10):755-765



©2018 by the Author(s); licensee Accademia Peloritana dei Pericolanti (Messina, Italy). This article is an open access article distributed under the terms and conditions of the Creative Commons Attribution 4.0 International License (<https://creativecommons.org/licenses/by/4.0/>).

Communicated and received June 26, 2018, revised July 19, 2018, published on line December 18, 2018